

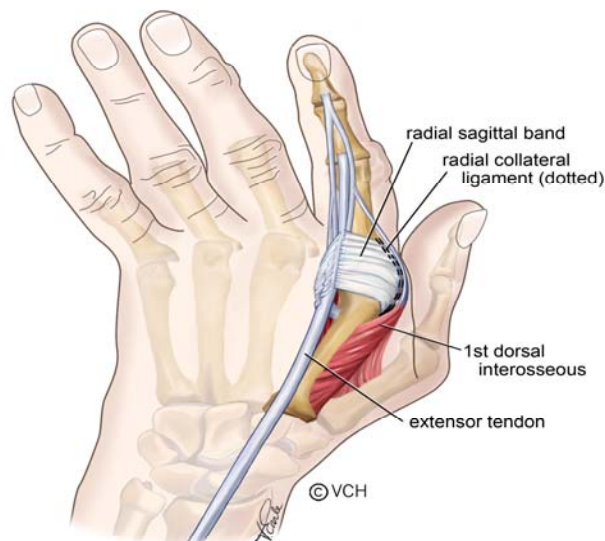
Best Practice Recommendations for Management of Ulnar Drift Deformity in Rheumatoid Arthritis

DESCRIPTION

Ulnar Drift deformity is characterized by ulnar deviation and volar subluxation of the metacarpal phalangeal (MCP) joints.

Site of Onset

In Rheumatoid Arthritis (RA), chronic inflammation of the MCP joints causes damage to the joint capsule and surrounding ligaments. Many factors contribute to the progression of this deformity.



Intrinsic Factors: 1, 2, 3

- MCP is a shallow ball and socket joint.
- There is an ulnar inclination of the phalanges relative to the metacarpals, with the greatest angle occurring at the index finger.
- Pain causes spasm of the intrinsic muscles and produces an increased flexion force at the MCPs and increased extension force at the proximal interphalangeal (PIP) joints.
- 1st dorsal interossei has a broad attachment to the joint capsule and the volar plate. With capsular distention, its action changes from abduction to flexion.
- Ulnar interossei are stronger than their radial counterparts.

Extrinsic Factors: ^{1, 2, 3}

- Stretched collateral ligaments and joint capsular distention allows bowstringing of flexor digitorum profundus (FDP) & flexor digitorum superficialis (FDS) promoting palmar subluxation.
- Thumb opposition produces a strong ulnar force against index finger.
- Flexor tendons pull in an ulnar direction at MCP joint.
- Radial deviation of wrist secondary to chronic wrist synovitis, creates an ulnar deviating force at the MCP joints.
- The weakened extensor mechanism at the MCP joints allows the extensor communis (EC) tendons to slip ulnarly and change their action to ulnar deviation and flexion.

Signs of Deformity ^{1, 2}

Early Signs:

- Weakness of 1st dorsal interossei
- Laxity of radial collateral ligaments
- Tightness of intrinsic muscles
- Ulnar displacement of flexor tendons, especially index and long fingers
- Ulnar deviation of fingers when MCP joints are held in extension

Later Signs:

- Volar subluxation of phalanges
- Lack of full active MCP joint extension, leading to flexion contracture
- Ulnar “slip“ of extensor tendons
- Tightness of hypothenar muscles
- Radial deviation of the wrist
- Dislocation of extensor carpi ulnaris (ECU) tendon
- Inability of thumb to oppose index finger

ASSESSMENT

Inflammation ^{4, 5}

Wrist Joint

- Feel for heat using dorsum of hand over joint.
- Observe for swelling* around joint.
- Palpate for joint effusion* by placing thumbs over the radiocarpal and midcarpal joints and apply pressure alternately, feeling for fluid fluctuation.
- If negative, palpate for tenderness by applying pressure over joint line of the radiocarpal and distal radioulnar joints.

- If negative, check for stress pain by applying overpressure at end of range in extension and ask if tender. If negative, stress in flexion.

MCP Joint

- Feel for heat using dorsum of hand over joint.
- Observe for swelling* around joint.
- Palpate for effusion*. While supporting MCP joint in 45° of flexion, place thumbs on either side of joint and alternately apply medial & lateral pressure. Feel for fluid fluctuation.
- If negative, palpate for tenderness by applying medial and lateral pressure to the joint line.
- If negative, check for stress pain by applying overpressure at end of range in extension, while supporting the proximal phalange.

*An **effusion** is an accumulation of synovial fluid within the joint capsule, while **swelling** refers to the build up of fluid both within the joint and in the soft tissue surrounding it.

Range of Motion

Wrist Joint

Flexion / Extension: Place goniometer on dorsum of wrist to measure wrist flexion and on palm for wrist extension. If joint is swollen or subluxed, place goniometer along ulnar border of forearm and 5th finger, with axis just distal to the ulnar head.⁶

Radial / Ulnar Deviation: Place goniometer on dorsum of forearm and hand with distal arm of goniometer lined up with long finger and axis at the intercarpal joint. Note if palmar subluxation is present.^{6,7}

MCP Joints

Flexion / Extension: Place goniometer on dorsal surface of joint. If joint is swollen or deformed, place it on lateral aspect of index and medial aspect of little finger.

Abduction / Adduction: If range is reduced, trace hand with fingers abducted and adducted. Use a ruler to measure the distance from fingertip to fingertip.^{6,7} Note if palmar subluxation is present.

Ulnar Deviation: Place axis of goniometer dorsally on MCP joint, stationary arm over the metacarpal and movable arm parallel to the proximal phalange,

measure degree of deformity. Ask patient to actively correct alignment and re-measure. Check if MCP joints can be passively realigned to neutral. Alternately, trace or photograph the hand in “palm-down” position.^{6, 7}

Joint and Ligament Tests

Wrist Joint

Instability of the Distal Radioulnar Joint (DRUJ) - Ballotement Test or Piano Key Test: Stabilize the distal end of the radius using a lateral pinch grip, with the opposite hand move the ulnar head in a dorsal / volar plane. Excessive motion indicates instability of the DRUJ. Note: Normal degree of laxity is highly variable therefore compare to opposite side.⁴⁰

Carpal Subluxation: To determine carpal instability when the carpus appears subluxed, apply a dorsally directed pressure to the pisiform and observe if the carpus moves into normal alignment. If the carpus subluxes when the pressure is removed, instability is present. If carpus cannot be realigned the deformity is fixed.⁹ Note: Record presence of carpal collapse, “dinner fork” deformity, radial deviation of wrist or prominent ulnar styloid.

MCP Joints

Collateral Ligament: MCP joint must be flexed to 90° to ensure the collateral ligament is taut. Grasp the proximal phalange and gently apply pressure to radial side and then to the ulnar side of phalange. If normal, no movement occurs.^{1, 10}

Volar Subluxation: With MCP joint in neutral, palpate along dorsal surface of proximal phalange from distal to proximal. If subluxation is present there will be a palpable “step” at MCP joint line.

Special Tests

Test for Rupture of ECU: Place wrist in extension and slight ulnar deviation. Apply pressure in the direction of flexion and radial deviation. If normal, patient is able to resist movement.

Test for Subluxation of EC: Support wrist in neutral, position MCP joint in flexion and ask patient to actively extend finger against resistance. Repeat test for each finger and observe the extensor tendon for ulnar subluxation.³⁰

Test for Extensor Lag of EC: Support wrist in neutral and ask patient to actively extend MCP joints with the IP joints flexed. MCP joint extension to neutral (0°) should occur.¹³

Test for Intrinsic Tightness and PIP Capsular Tightness (Bunnel-Littler): Hold MCP joint in maximum extension and passively flex PIP joint, stretching the intrinsics. Next, place MCP joint in flexion (relaxing the intrinsics), passively flex the PIP joint and note the difference in PIP joint range. If range increases when the MCP joint is flexed, the intrinsics are tight. If PIP joint cannot be fully flexed limitation is likely due to PIP joint capsular tightness. Repeat test for each finger. Test is not valid if MCP joint is subluxed or a fixed Swan Neck deformity (SND) exists.¹¹

Test for Tightness of Ulnar & Radial Intrinsics: Hold MCP joint in maximum extension and slight radial deviation. Passively flex PIP joint, noting PIP joint flexion range. Next place MCP joint in full flexion and slight radial deviation, passively flex the PIP joint. If PIP joint flexion increases with MCP joint flexion, the ulnar intrinsics are tight. For radial intrinsic tightness, repeat test with MCP joint in slight ulnar deviation. Test is not valid if MCP joint is subluxed or fixed SND exists.

Test for Lumbrical Tightness: Ask the patient to make a composite (full fist). If there is paradoxical DIPJ extension with full MCPJ flexion, this is considered a positive test for lumbrical tightness.¹⁹

Test for 1st Dorsal Interosseus: With palm flat on table, ask patient to actively abduct index finger while applying resistance to the radial side of the proximal phalange.³⁹

Test for Flexor Tendon Subluxation: While palpating FDP on flexor aspect of palm or on the ulnar surface of the proximal phalange, ask the patient to flex the finger against resistance. Feel for ulnar displacement of tendon.²

Test for Ulnar Fovea Sign: Elbow in $\sim 90^{\circ}$ – 110° flexion, forearm & wrist in neutral rotation. Examiner presses thumb into the ulnar fovea ('soft spot' between the ulnar styloid process and FCU tendon). Test is considered positive for ulnar foveal disruption or ulnar triquetral ligament injury when tenderness replicates the patient's pain in terms of character and location.³⁵

Hand Function

Fist: Ask patient to make a fist. If impaired, measure distance from fingertips to proximal palmar crease,¹² or record % of full fist.

Tuck: Measure distance from fingertips to palmar digital crease, at base of fingers,¹³ or record % of full tuck.

Pinch Strength: Use a pinch gauge to measure strength of "tripod" pinch. The patient should be comfortably seated. Position shoulder in adduction and neutral rotation, elbow at 90° flexion, forearm in mid-rotation and wrist in 15° - 30° extension. Repeat 3 times and average scores.^{14, 15}

Grip Strength: An adapted sphygmomanometer is easier to use, though less reliable than JAMAR, for the hand with arthritis.^{14, 15} A Vigorimeter can also be used. The test position is the same as above. Repeat 3 times and average scores.^{14,15}

Opposition: Ask patient to make a circle, using tip of thumb to each fingertip. Note shape of circle (round or oval). If unable to reach fingertip, note location on finger where patient can oppose, or use a ruler to measure the distance from fingertip to tip of thumb.¹²

Dexterity: Ask patient if they have difficulties writing, doing up buttons or small fasteners, and picking up coins from a table and holding them in palm. Standardized tests are available in Dexterity section of the MPAP Arthritis Hand Function Test (AHFT)¹⁶ or Section II of the Michigan Hand Outcomes Questionnaire.²⁹

Hand Span: Ask patient to open hand (fully extend and abduct fingers and thumb). To document place palm down on table, trace or photograph hand.

TREATMENT

Modalities

- Ice to decrease swelling and pain³¹
- Contrast baths to decrease swelling
- Moist heat applied with hand positioned at end of available range to increase stretch³¹
- Laser to decrease pain^{17, 32}
- Ultrasound in water to decrease joint tenderness^{17, 32}
- Transcutaneous Nerve Stimulation (TNS) to decrease pain^{17,32}
- Wax followed by hand exercises^{17, 32}

Exercise

- Acute inflammation of joint can cause reduced tensile strength of tissue, therefore, stretching exercises should be avoided while joint is inflamed due to risk of overstretching and tearing tissue.^{33, 34}
- Active and passive ROM for MCP, PIP, DIP joints.¹⁸
- Intrinsic Stretches: Lumbricals: To actively stretch the lumbricals, ask patient to actively flex DIP and PIP joints with MCP joints in extension.¹⁹ Hold stretch for 10 –30 seconds ~ 2 – 5 minutes⁴¹, 3 – 4 reps, 2 – 3 times per week or daily if possible³³ Interossei: To passively stretch the interossei, hold the MCP in hyperextension and passively flex the PIP joint as much as possible.¹⁹ Hold stretch for 10–30 seconds ~ 2–5 minutes⁴¹, 3 – 4 reps, 2 – 3 times per week or daily if possible³³

- Isometric strengthening of radial intrinsic: With palm flat on table, place a pencil on the radial side of each finger and resist movement of finger radially. Hold for 6 seconds, 5 –10 reps, at least once per day.
- Radial “finger walking”: With palm flat on table, extend thumb and then actively move fingers towards the thumb.¹⁸
- Tendon Gliding: Start with fingers straight. (1) Flex the MCP joints keeping PIP & DIP joints straight, to form a “tabletop”. Return to start position. (2) Flex PIP & DIP joints, keeping MCP joints straight to form a “tuck”. Return to start position. (3) Flex PIP & MCP joints while keeping DIP joints straight, to form a “straight fist”. (4) Flex MCP, PIP, & DIP joints to form a full “fist”.²¹

Splinting

Hand Resting Splint

- Purpose: To reduce pain by providing local rest and support to the wrist, the MCP and the IP joints; to reduce subluxation at the wrist; to position the MCP joints in neutral radial-ulnar alignment and to reduce MCP joint subluxation by supporting the proximal phalanges.^{22, 23, 24,36} (see OTIIA-7)
- Indications: Pain at night, MCP joint inflammation, tendinopathy, risk of tendon rupture. Splints are useful for patients who sleep with hands flexed or have soft tissue contracture due progressive deformity.^{1,14, 22, 23, 24,37}
- Description: It is a lightweight, thermoplastic, palmar-based splint that supports proximal 2/3 of forearm, wrist and hand. Wrist is positioned in 10 - 15° extension & 5 -10° ulnar deviation, forearm in ¾ prone, MCP joints in 15 -20° flexion & neutral alignment, PIP & DIP joints in slight flexion. With MCP joint subluxation, support the palmar arch to avoid tilting the base of proximal phalanges into head of the metacarpals as this may increase pain and bony absorption of metacarpal heads. Appropriate strapping and finger dividers are required to preserve the corrected position of wrist and hand in the splint.^{14, 22, 25,}
- Wearing Regime: Resting splints should be worn at night and during daytime rest periods when hands are painful and inflamed. Start by wearing splint for 30 minutes, check skin for redness, then increase wearing time as tolerated. (see OTIID-2)
- Precautions: It is difficult to wear splints on both hands, therefore they are often worn alternatively. Frequent night toileting may interfere with splint use. Warm water soaks and daily ROM exercises should be recommended to prevent joint stiffness.²² Monitor proximal joints as weight of splint can aggravate shoulder and elbow. Use of a supporting pillow under arm is encouraged.

MPAP MCP Protection Splint ²⁶

- Purpose: To provide support and improve alignment of MCP joints during periods of activity and rest. (see OTIIA-9)
- Indications: Pain, MCP joint inflammation, MCP joint instability, MCP joint subluxation, flexor tendinopathy, intrinsic muscle tightness, ulnar drift, decreased hand function (pinch & grasp).^{1, 24, 26, 27,38}
- Description: It is a volar thermoplastic splint that supports the MCP joints. MCP joints are positioned in 30° of flexion & neutral alignment. Finger dividers extend high enough to maintain neutral alignment during hand activity and are thin enough to prevent finger abduction. The ulnar border extends to PIP joint of fifth finger to control ulnar deviation. This splint can be fabricated with a thumb opening for better stability. (see OTIIA-8)
- Wearing Regime: MCP splints are worn during activities that cause pain and stress to MCP joints. With advanced ulnar drift, it can reposition the fingers in neutral to facilitate pinch and grasp. It may also be worn as a nighttime “resting splint” during periods of inflammation. Patients should be motivated to use this splint. (see OTIID-6)
- Precautions: Daily ROM exercises are recommended. The splint should not limit PIP joint flexion, thumb flexion & adduction or wrist flexion. Watch for pressure areas on ulnar border of proximal phalanges against dividers.
- Contraindications: It may aggravate PIP joint inflammation. If PIP joint flexion is limited splint can impair hand function.

Other MCP Splint Options ¹

- Volar Bar with Anti-deviation Straps (custom): A rarely used splint, it is useful for mild, correctible deformity without MCP joint inflammation. Avoid pressure on radial border of second metacarpal and splaying of fingers due to splint bulk. Patients may find strapping complicated.
- Anatech Soft Anti-ulnar Deviation Splint (commercial): It is a neoprene hand-based, wrap-style splint. Although rarely used, it may be useful for mild, correctible deformity, sometimes used as a night splint. Patient may be allergic to material. (see OTIID-7a&b)
- Rehband Wrist & Ulnar Deviation Splint (commercial): It is a lycra wrist splint, extended to include MCP joints. It can be worn during day or at

night, for wrist & MCP joint inflammation, pain, and early MCP joint laxity. Also useful when MCP joints cannot be corrected without wrist stabilization. It may be difficult to put on and can cause pressure in web space. It is not useful for severe ulnar drift.

- **Oval & Polycentric Hinged Splint** (commercial): A dorsal- based plastic splint, hinged at MCP joint to allow free MCP joint range. Open palm enhances grasp and sensation. Bendable stays position fingers in neutral. Useful for mild to moderate deviation.

Exercise Splint ¹⁹

- **Purpose:** To block MCP joint flexion in order to facilitate stretching the intrinsic muscles.
- **Indications:** MCP joint inflammation, intrinsic tightness
- **Description:** It is a hand- based splint that maintains MCP joint in full extension or hyperextension.
- **Wearing Regime:** To be worn for exercise only. With the MCP joints held in extension by the splint, ask patient to flex DIP and PIP joints. Hold stretch for 10 –30 seconds, 3 – 4reps, 2 – 3 times per week or daily if possible. ³³
- **Precautions:** Splint places dynamic traction on PIP joint in flexion so may aggravate PIP joint inflammation.
- **Contraindications:** It is not appropriate for subluxed MCP joints and should be discontinued if it increases MCP joint pain.

Joint Protection Techniques ^{1, 15, 28}

- Avoid stress on MCP joints by using both palms instead of fingers to grasp objects such as holding a tray or book.
- Avoid activities that use lateral pinch, such as turning a key or pulling a file. Try to use a “tip to tip” pinch instead.
- Avoid activities that move the fingers in an ulnar direction, such as turning a doorknob or a jar lid, or stirring with a wooden spoon. Try to use a radially directed movement instead.
- Avoid direct external pressure on MCP joints, such as pushing on MCP joints when getting up from a chair or resting chin on MCP joints.
- Avoid hand positions that hold the MCP joints in flexion and IP joints in extension such as holding a book or magazine.
- Avoid activities that increase pull of gravity on MCP joints such as holding a heavy coffee mug by the handle. Use both hands with an insulated mug.

Note: These recommendations are based on materials ranging from systematic reviews, published studies, expert opinion, reviews of clinical texts and the expertise of the physiotherapists and occupational therapists at the Mary Pack Arthritis Program.

REFERENCES

1. Bielefeld, T et al. The Unstable Metacarpophalangeal Joint in Rheumatoid Arthritis: Anatomy, Pathomechanics and Physical Rehabilitation Considerations. *Journal of Orthopaedic and Sports Physical Therapy* 2005;35-8:502-520.
2. Flatt A. Ulnar Drift. *Journal of Hand Therapy*. 1996;Oct/Dec: 282-292.
3. Melvin JL. *Rheumatic Disease in the Adult and Child: Occupational Therapy and Rehabilitation*. 3rded. F.A. Davis Co:1989;284.
4. Klinkhoff A. et al. An Experiment in Reducing Interobserver Variability of the Examination for Joint Tenderness. *Journal of Rheumatology* 1988;5-3:492-494
5. Bombardier, C. et al. *Illustrated Guide to a Standard Examination for Joint Tenderness and Swelling*.1987
6. Adams, LS et al. *Range of Motion: American Society of Hand Therapists (ASHT) Clinical Assessment Recommendations*. 2nd Edition. Chicago:1992.
7. Hoppenfeld, S. *Physical Examination of the Spine and Extremities*. Prentice-Hall:1976;88-91.
8. Melvin JL. *Rheumatic Disease in the Adult and Child: Occupational Therapy and Rehabilitation*. 3rded. F.A. Davis Co:1989;281-282.
9. Ruby LK (editor). *Hand Clinics - Rheumatoid Arthritis of the Hand and Wrist*. 1996;12:501.
10. Magee DJ. *Orthopedic Physical Assessment*. 4thed. Saunders:2002;392-393.
11. Hoppenfeld, S. *Physical Examination of the Spine and Extremities*. Prentice-Hall:1976;101-102.
12. Melvin JL. *Rheumatic Disease in the Adult and Child: Occupational Therapy and Rehabilitation*. 3rded. F.A. Davis Co:1989;346-347.
13. Mackin EJ, Callahan AD, Skirven TM et al (editors). *Rehabilitation of the Hand and Upper Extremity*. 5th ed. Mosby: 2002;123-126.
14. Mackin EJ, Callahan AD, Skirven TM et al (editors). *Rehabilitation of the Hand and Upper Extremity*. 5th ed. Mosby: 2002;1573- 1575.
15. Melvin JL. *Rheumatic Disease in the Adult and Child: Occupational Therapy and Rehabilitation*. 3rded. F.A. Davis Co:1989;352-355.
16. Backman C et al. Arthritis Hand Function Test: Development of a Standardized Assessment Tool. *Occupational Therapy Journal of Research* 1991;11-4:245-256.
17. Ottawa Panel Evidence-Based Clinical Practice Guidelines for Electrotherapy and Thermotherapy Interventions in the Management of Rheumatoid Arthritis in Adults. *Physical Therapy* 2004;84-11:1016-1043.
18. O'Brien AV, Jones P, Mullis R et al. Conservative Hand Therapy Treatments in Rheumatoid Arthritis - A Randomized Controlled Trial. *Rheumatology* 2006;45:577-583.
19. Harrell P. Biomechanics of the Hand. ARHP Audioconference: June 16, 2005.
20. Wehbe M. Tendon Guiding Exercises. *Am JOT*1987;41:3:164-167.
21. Michlovitz, S. Conservative Interventions for Carpal Tunnel Syndrome. *J Orthop & Sports Phy Ther* 2004; 34:10: 589-600.
22. Mary Pack Arthritis Program, Occupational Therapy Dept, OTIIA-7 Hand Resting Splint Protocol. 2004.
23. Steultjens E. et al. Occupational Therapy for Rheumatoid Arthritis: A Systematic Review. *Arthritis & Rheumatism* 2002;47-6:672-685.
24. Adams J et al. Static Orthoses in the Prevention of Hand Dysfunction in Rheumatoid Arthritis: A Review of the Literature. *Musculoskeletal Care* 2005;3-2;85-101.

- 25 Melvin JL. Rheumatic Disease in the Adult and Child: Occupational Therapy and Rehabilitation. 3rded. F.A. Davis Co:1989;399-400.
- 26 Mary Pack Arthritis Program, Occupational Therapy Dept, OTIIA-9 MCP Protection Splint Protocol. 2004.
- 27 Rennie HJ. Evaluation of the Effectiveness of Metacarpophalangeal Ulnar Deviation Orthosis. J Hand Therapy 1996;9:371-377.
- 28 Mackin EJ, Callahan AD, Skirven TM et al (editors). Rehabilitation of the Hand and Upper Extremity. 5th ed. Mosby: 2002:1579-1580.
- 29 Chung KC et al. Reliability and Validity Testing of the Michigan Hand Outcome Questionnaire. Journal of Hand Surgery 1998;23A:575-587.
- 30 Shinohara T, Nakamura R, Suzuki M et al. Extensor Mechanism Laxity at the Metacarpal Joint as Identified by a New Provocative Test - Predisposition to Dislocation. Journal of Hand Surgery 2005; 30B: 79-82.
- 31 Mackin EJ, Callahan AD, Skirven TM et al (editors). Rehabilitation of the Hand and Upper Extremity. 5th ed. Mosby: 2002: 1748-50
- 32 Cochrane Musculoskeletal group Cochrane Database of Systematic Reviews 1, 2006:
Robinson et al. Thermotherapy for treating rheumatoid arthritis Robinson et al.; Brousseau L et al.
Transcutaneous electrical nerve stimulation for the treatment of rheumatoid arthritis in the hand; Casimiro et al.
Therapeutic ultrasound for the treatment of rheumatoid arthritis; Brousseau L et al. Low-level laser (class
1,11,111) for treating rheumatoid arthritis.
- 33 Westby MD, Minor MA. Exercise and Physical Activity. In: Clinical Care in the Rheumatic Diseases. 3rd ed. Atlanta: Association of Rheumatology Health Professionals:2006;211-220.
- 34 Myths and Truths of Stretching; Orthopedic Division Review. Jan/Feb 2001
- 35 Tay SC, Tomita K, Berger RA. The "Ulnar Fovea Sign" for Defining Ulnar Wrist Pain - An Analysis of Sensitivity and Specificity. J Hand Surg 2007;32A:438-444
- 36 Silva AC, Jones A, Silva PG et al. Effectiveness of a Night-Time Hand Positioning Splint in Rheumatoid Arthritis: A Randomized Controlled Trial. J Rehabil Med 2008;40:749-754
- 37 Biese J. Therapist's Evaluation and Conservative Management of Rheumatoid Arthritis in the Hand and Wrist. 5th Edition. Missouri: Mosby 2002:1569-1582
- 38 Formsa S, van der Sluis C, Dijkstra P, Effectiveness of a MP j- blocking splint and therapy in rheumatoid arthritis: a descriptive pilot study. Journal of Hand Therapy 2008;21:347-353.
- 39 Melvin JL. Rheumatic Disease in the Adult and Child: Occupational Therapy and Rehabilitation. 3rded. F.A. Davis Co:1989;293.
- 40 Aoki M, Moriya T, Iba Y. et. al. Effect of triangular ligament tears on distal radioulnar joint instability and evaluation of three clinical tests: A biomechanical study. J Hand Surg 2009;34:219-223.
- 41 Hoens A. Evidence-Informed Practice for Range of Motion, Stretching and Prolonged Positioning. Providence Health Care - Physiotherapy Services. 2011.